Case Report

J Trauma Inj 2022;35(Suppl 1):S18-S22
https://doi.org/10.20408/jti.2021.0091

Journal of Trauma and Injury JTI

pISSN 2799-4317 • eISSN 2287-1683

Salvation of a solitary kidney in a patient with grade IV renal trauma: a case report

Hyuntack Shin, MD[1], Ae Jin Sung, MD[1], Min A Lee, MD[2], Jayun Cho, MD[2], Gil Jae Lee, MD[2], Byungchul Yu, MD[2], Kang Kook Choi, MD[2]

[1]Department of Emergency Medicine, Gyeongsang National University College of Medicine, Jinju, Korea
[2]Department of Traumatology, Gachon University Gil Medical Center, Gachon University College of Medicine, Incheon, Korea

Received: October 29, 2021
Revised: December 15, 2021
Accepted: December 20, 2021

Correspondence to
Kang Kook Choi, MD
Department of Traumatology, Gachon University Gil Medical Center, Gachon University College of Medicine, 21 Namdong-daero 774beon-gil, Namdong-gu, Incheon 21565, Korea
Tel: +82-32-460-3010
E-mail: choikangkook@gachon.ac.kr

There are many reasons for solitary kidney. Congenital causes include renal agenesis and dysplasia. Acquired causes include nephrectomy performed for reasons including traumatic kidney injury, disease (e.g., renal cell carcinoma), and donation for kidney transplantation. According to the European Association of Urology, the World Society of Emergency Surgery, and the American Association for the Surgery of Trauma guidelines, it is important to preserve the remaining renal function as much as possible when a solitary kidney patient has suffered a traumatic kidney injury. The authors present a case of kidney preservation in a solitary kidney patient with a traumatic grade IV renal injury through non-operative management involving superselective renal artery angioembolization.

Keywords: Renal injury; Solitary kidney; Therapeutic embolization; Case reports

INTRODUCTION

Solitary kidney, which has various causes, is a condition in which a person has a single kidney. Congenital causes include renal agenesis and renal dysplasia [1]. The major acquired cause is unilateral nephrectomy for reasons such as renal trauma, disease (e.g., renal cell carcinoma), and donation for kidney transplantation [2]. According to the annual statistics of the Korea Organ Donation Agency, the renal transplantation rate in Korea has been increasing every year and 848 kidney transplants were performed in 2020 [3]. Therefore, as the number of kidney donors increases, solitary-kidney patients are increasing.

A high-grade kidney injury is defined as an American Association for the Surgery of Trauma (AAST) grade IV or V injury. AAST grade IV refers to parenchymal laceration extending through the renal cortex, medulla, and collecting system, and in the vascular case, it is the main renal artery or vein injury with contained hemorrhage. AAST grade V is a state of completely shattered kidney or avulsion of the renal hilum [4]. According to recent protocols, the initial management of renal trauma depends on hemodynamic status rather than the grade of the injury. For hemodynamically stable patients, conservative management, including expectant management or angioembolization, is recommended [5,6]. According to the European Association of Urology, the World Society of Emergency Surgery (WSES) and AAST, surgical management should be considered for hemodynamically unstable patients [4,7]. Unfortunately, surgical

management for unstable patients usually ends in unilateral nephrectomy [8]. For patients who have bilateral kidneys, this is not a lethal outcome, but for solitary-kidney patients, it can be a critical problem. Once nephrectomy occurs in patients who have a traumatic high-grade renal injury with solitary kidney, the patient must undergo lifelong dialysis or wait for kidney transplantation. Korea suffers from a shortage of organ donors, and long-term dialysis has the risk of various complications and mortality.

In recent studies, superselective embolization for high-grade renal trauma has been reported to show a high therapeutic success rate for hemostasis and a higher likelihood of kidney preservation than operative treatment [9,10]. Herein, we report a case of successful salvation of a solitary kidney in a patient with grade IV renal trauma by two sequential procedures of selective angioembolization and cystoscopic intra-cystic hematoma evacuation. Written informed consent for publication of the research details and clinical images was obtained from the patient.

CASE REPORT

A 52-year-old male patient who had lived with a solitary right kidney after donating his left kidney to his father 20 years ago was transferred to a nearby hospital due to right flank pain that occurred after a motorcycle accident. An AAST grade IV right kidney injury was found on abdominal computed tomography (Fig. 1). He was transferred to Gachon University Gil Medical Center for further treatment. When he arrived, his vital signs were as follows: systolic blood pressure, 100 mmHg; diastolic blood pressure, 60 mmHg; heart rate, 73 beats/min; respiratory rate, 15 breaths/min; and body temperature, 36.0°C. His Glasgow Coma Scale score was 15. On an abdominal computed tomography scan taken at a previous hospital, the lower pole of the right kidney was shattered, accompanied by extravasation of contrast (Fig. 1). The upper pole of the right kidney was relatively preserved. After a Foley catheter was inserted, gross hematuria with blood clots was identified. Because the patient presented in a hemodynamically stable condition, we decided to preserve the remaining kidney through selective renal artery embolization. Renal angiography (Fig. 2) demonstrated a pseudoaneurysm with a diameter of 0.7 cm at the anterior superior segmental artery, a pseudoaneurysm with a diameter of 0.1 cm at the anterior inferior segmental artery, and mild irregularity of the subsegmental arteries from the posterior inferior segmental ar-

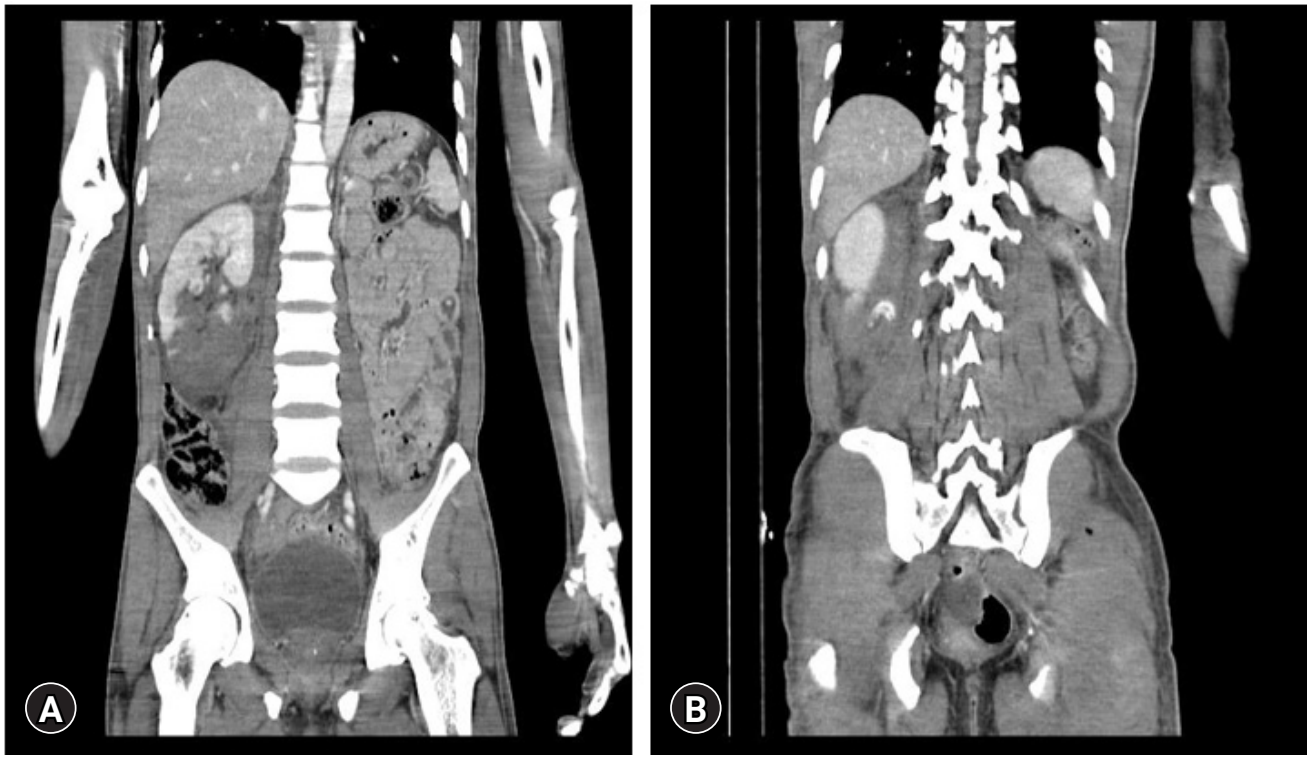

Fig. 1. Coronal view of contrast-enhanced computed tomography shows (A) a shattered low pole of the right kidney and (B) extravasation of contrast. A perirenal hematoma was also present.

tery. Embolization was performed on the pseudoaneurysm at the anterior superior segmental artery using a microcoil. Small lesions, which were suspicious for pseudoaneurysms, were observed in the anterior inferior segmental artery and the posterior inferior segmental artery, but no additional treatment was performed to preserve the viable kidney portion that would be damaged by embolization of the lesion. After embolization, the patient was transferred to the trauma intensive care unit. In the trauma intensive care unit, gross hematuria was shown. Continuous bladder irrigation (200 mL/hr) was performed. Nevertheless, the Foley catheter was frequently occluded due to clots. On the third day of hospitalization, we consulted an interventional radiologist for renal angiography to check the remnant bleeding focus. Renal angiography showed an arteriovenous fistula in the inferior pole in the right kidney (Fig. 3). Embolization with four microcoils (MicroNester with 2 mm/5 cm [Cook Medical, Bloomington, IN, USA], Concerto with 2 mm/4 cm [Medtronic, Minneapolis, MN, USA], and two Concerto microcoils with 2 mm/8 cm [Medtronic]) was done to the blood vessel. Next, we consulted a urologist for evacuation of the bladder hematoma. Ellik evacuation was done to remove the bladder hematoma. There was no definite active bleeding site in the bladder. After that, there was no definite blood clot and hematuria through the Foley catheter. Clear urine was discharged through the Foley catheter at a rate of 80 to 170 mL/hr. His initial creatinine level was 1.26 mg/dL (glomerular filtration rate by the 2021 Chronic Kidney Disease Epidemiology Collaboration equation, 69 mL/min/1.73 m^2) and his creatinine levels were checked daily. The highest creatinine level in his hospital stay was 1.69 mg/dL (glomerular filtration rate, 44 mL/min/1.73 m^2) on the third day of hospitalization. On the next day, the creatinine level was 1.61 mg/dL (glomerular filtration rate, 51 mL/min/1.73 m^2). There was no definite pulmonary edema on a chest X-ray or pitting edema in the bilateral lower extremities. On the fifth day of hospitalization, the patient was transferred to the general ward, and on the 10th day of hospitalization, the patient was discharged uneventfully.

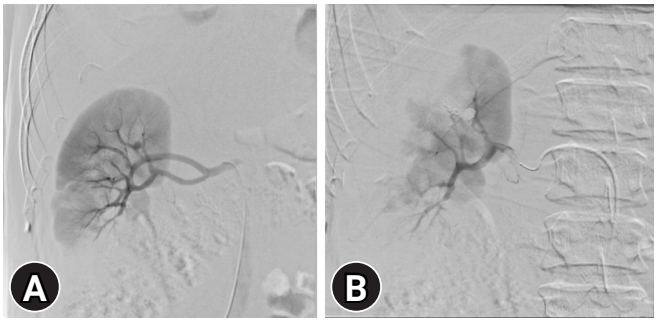

Fig. 2. Psudoaneurysm in arteriogram of right kidney. (A) Arteriogram of the right main artery shows a pseudoaneurysm at the anterior superior segmental artery. (B) Embolization was done with a microcoil.

DISCUSSION

We saved a solitary kidney through multiple procedures in a case of high-grade renal trauma, and this experience can be helpful for the management of solitary-kidney trauma. Although the patient had a high-grade kidney injury, we could easily refer the patient to an interventional radiologist for initial therapy due to the

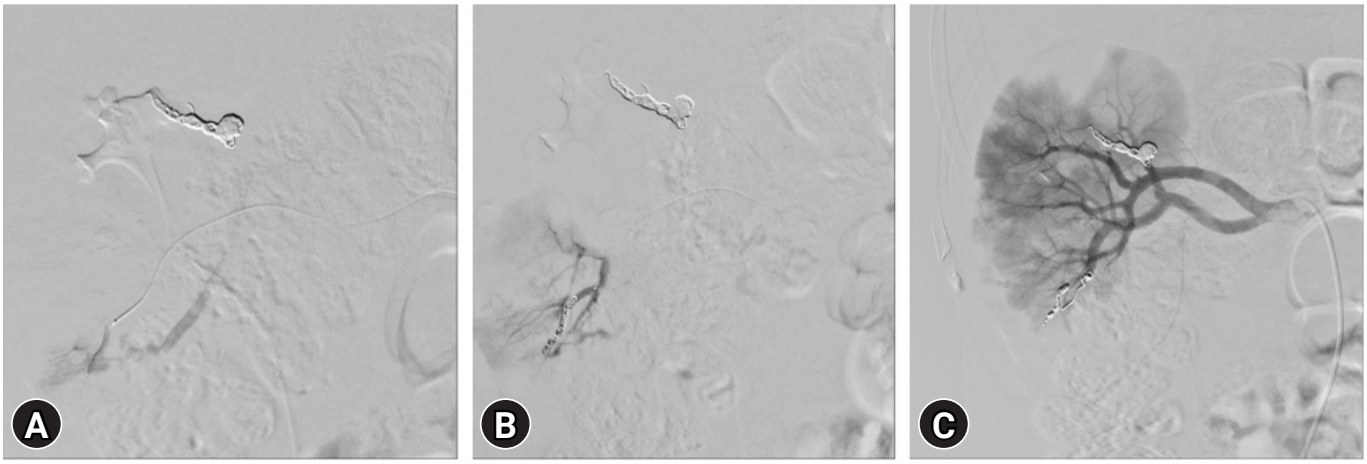

Fig. 3. Fistula in areriogram of right kidney. (A, B) Arteriovenous fistula appears in the inferior pole of the right kidney. (C) Embolization with four microcoils (MicroNester with 2 mm/5 cm [Cook Medical, Bloomington, IN, USA], Concerto with 2 mm/4 cm [Medtronic, Minneapolis, MN, USA], and two Concerto microcoils with 2 mm/8 cm [Medtronic]) was done.

https://doi.org/10.20408/jti.2021.0091

patient's hemodynamic stability. Our hospital is a regional trauma center where an interventional radiologist is available at all times. Renal artery embolization was performed in a superselective manner to preserve the remaining kidney as much as possible. After follow-up for remnant suspicious bleeding foci, embolization was additionally performed through follow-up angiography.

According to the WSES and AAST guidelines, it is recommended to consider superselective embolization in hemodynamically stable or hemodynamically stabilized solitary-kidney patients [4]. Although controversial, some recent studies have suggested that renal artery embolization be performed even in hemodynamically unstable patients [11,12]. In hemodynamically unstable solitary-kidney patients, an option could be to perform renal artery embolization accompanied with sufficient resuscitation and critical care. Even if embolization is not supported or surgery is unavoidable due to delay in embolization, renal salvation procedures such as renorrhaphy or partial nephrectomy should be tried to save the kidney as much as possible. If a salvage operation is performed, insertion of a double-J stent will be helpful for the anticipated postoperative urinary leakage.

As in the case described herein, gross hematuria may cause Foley catheter occlusion, so caution should be taken, and cystoscopic evacuation of bladder hematoma is useful. It is known that the higher the AAST renal injury grade, the lower the remnant renal function, which is also correlated with the findings of dimercaptosuccinic acid renal scans [13]. There are no guidelines on using dimercaptosuccinic acid scans to monitor residual renal function after traumatic kidney injury. Further research could provide details on the relationship between observed remnant kidney function in solitary-kidney patients through dimercaptosuccinic acid and the patient's predicted prognosis.

NOTES

Ethical statements

Written informed consent for publication of the research details and clinical images was obtained from the patient.

Conflicts of interest

Gil Jae Lee is the Editor-in-Chief, Min A Lee is the Associate Editor, and Jayun Cho and Kang Kook Choi are Editorial Board members of *Journal of Trauma and Injury* but were not involved in the peer reviewer selection, evaluation, or decision process of this article. The authors have no other conflicts of interest to declare.

Funding

None.

Author contributions

Conceptualization: all authors; Data curation: all authors; Formal analysis: all authors; Methodology: all authors; Project administration: all authors; Resources: all authors; Supervision: all authors; Validation: all authors; Visualization: all authors; Writing–original draft: HS, MAL, JC, GJL, BY; Writing–review & editing: KKC.

All authors read and approved the final manuscript.

REFERENCES

1. Ordon M, Welk B, McArthur E, et al. Risk of nephrectomy in previous living kidney donors. Transplantation 2016;100:1313–7.
2. Cochat P, Febvey O, Bacchetta J, Berard E, Cabrera N, Dubourg L. Towards adulthood with a solitary kidney. Pediatr Nephrol 2019;34:2311–23.
3. Korea Organ Donation Agency (KODA). Annual report [Internet]. Seoul: KODA; 2020 [cited 2021 Oct 8]. Available from: https://www.koda1458.kr/info/transplant.do.
4. Coccolini F, Moore EE, Kluger Y, et al. Kidney and uro-trauma: WSES-AAST guidelines. World J Emerg Surg 2019;14:54.
5. Liguori G, Rebez G, Larcher A, et al. The role of angioembolization in the management of blunt renal injuries: a systematic review. BMC Urol 2021;21:104.
6. Petrone P, Perez-Calvo J, Brathwaite C, Islam S, Joseph DK. Traumatic kidney injuries: a systematic review and meta-analysis. Int J Surg 2020;74:13–21.
7. Serafetinides E, Kitrey ND, Djakovic N, et al. Review of the current management of upper urinary tract injuries by the EAU Trauma Guidelines Panel. Eur Urol 2015;67:930–6.
8. Wessells H, Suh D, Porter JR, et al. Renal injury and operative management in the United States: results of a population-based study. J Trauma 2003;54:423–30.
9. van der Wilden GM, Velmahos GC, Joseph DK, et al. Successful nonoperative management of the most severe blunt renal injuries: a multicenter study of the research consortium of New England Centers for Trauma. JAMA Surg 2013;148:924–31.

10. Sarani B, Powell E, Taddeo J, et al. Contemporary comparison of surgical and interventional arteriography management of blunt renal injury. J Vasc Interv Radiol 2011;22:723–8.
11. Jairam A, King B, Berman Z, Rivera-Sanfeliz G. Non-permanent transcatheter proximal renal artery embolization for a grade 5 renal injury with delayed recanalization and preserved renal parenchymal enhancement. J Trauma Inj 2021;34:198–202.
12. Desai D, Ong M, Lah K, Clouston J, Pearch B, Gianduzzo T. Outcome of angioembolization for blunt renal trauma in haemodynamically unstable patients: 10-year analysis of Queensland public hospitals. ANZ J Surg 2020;90:1705–9.
13. Tasian GE, Aaronson DS, McAninch JW. Evaluation of renal function after major renal injury: correlation with the American Association for the Surgery of Trauma Injury Scale. J Urol 2010;183:196–200.