Case Report

J Trauma Inj 2022;35(Suppl 1):S40-S45
https://doi.org/10.20408/jti.2022.0016

Journal of Trauma and Injury JTI

pISSN 2799-4317 • eISSN 2287-1683

Detection of pharyngeal perforation during fiberoptic endoscopic evaluation of swallowing in a person with cervical spinal cord injury in the intensive care unit: a case report

Min Soo Choi, MD[1], Sang Hun Han, MD[1], Yong Beom Shin, MD[1,2], Myung Hun Jang, MD[1]

[1]Department of Rehabilitation Medicine, Biomedical Research Institute, Pusan National University Hospital, Busan, Korea
[2]Department of Rehabilitation Medicine, Pusan National University School of Medicine, Busan, Korea

Endotracheal tube insertion and mechanical ventilation are indicated in spinal cord injury patients; however, dysphagia can occur after extubation. The resultant complications of dysphagia may increase the length of hospital stay and mortality. Therefore, dysphagia should be evaluated after extubation. This case report introduces a rare case of finding pharyngeal perforation during the fiberoptic endoscopic evaluation of swallowing (FEES) in patients with cervical spine injuries in the intensive care unit. A 71-year-old male patient met with a road traffic accident. The patient underwent C3–4 posterior fusion and C3–4 anterior cervical discectomy and fusion. After successful extubation, the patient underwent FEES to assess swallowing function. During FEES, the metallic plate was found to be exposed through mucosal erosion, and swelling was observed at the surgical site at the hypopharynx. The nasogastric tube was removed to prevent secondary damage and infection at the operation site and the patient was received conservative therapy. The FEES endoscope machine is portable so it can be easily applied at the bedside to intensive care unit patients. In addition, FEES allows the identification of anatomical abnormalities of the oropharynx and abnormalities of vocal cord. Thus, it is recommended to do FEES to check anatomical abnormalities as well as dysphagia in patients in the intensive care unit.

Keywords: Spinal cord injuries; Intensive care units; Dysphagia; Endoscopy; Case reports

Received: March 23, 2022
Revised: April 20, 2022
Accepted: May 2, 2022

Correspondence to
Myung Hun Jang, MD
Department of Rehabilitation Medicine, Biomedical Research Institute, Pusan National University Hospital, 179 Gudeok-ro, Seo-gu, Busan 49241, Korea
Tel: +82-51-240-7485
E-mail: zmh1048@naver.com

INTRODUCTION

Patients with severe trauma are prone to respiratory failure, requiring endotracheal tube insertion and mechanical ventilation. After extubation, however, swallowing dysfunction, also known as dysphagia, can occur frequently. The occurrence of postextubation dysphagia (PED) among patients admitted to the intensive care unit (ICU) is relatively common, and the frequency is reported to be about 93% [1].

Among patients with trauma, those with cervical spinal cord

injury (CSCI) are at a higher risk of dysphagia. A study reported that 16% of CSCI patients suffer from dysphagia during their first feeding, and the level of tetraplegia, reduction of the value of the lung volume and the subglottic pressure resulting from tracheostomy or thorax trauma, and the duration of ventilation are all significant factors in the development of dysphagia [2].

Complications of dysphagia include aspiration which has the potential to cause pneumonia, mechanical bronchial obstruction, transient hypoxemia, bronchospasm, and atelectasis. In addition, these complications may increase the length of hospital stay, delay the rehabilitation process, and increase mortality [3,4].

Therefore, after successful extubation, an evaluation of PED should be performed in the early stage of the traumatic CSCI. Both video fluoroscopic swallowing study (VFSS) and fiberoptic endoscopic evaluation of swallowing (FEES) are gold standard techniques for the assessment of dysphagia. Because FEES offers the advantages of better accessibility and direct observation of the laryngeal anatomy, it is preferred for the evaluation of patients in the ICU. Herein, we report a case demonstrating the importance of FEES after extubation in CSCI patients. What makes our case report special is that it is the first study reporting that found perforation of hypopharynx in the FEES. The patient provided written informed consent for publication of the research details and clinical images.

CASE REPORT

A 71-year-old male patient met with a road traffic accident and complained of inability to move all four limbs. On arrival, the patient was alert. On the initial physical examination, the key muscle power was found to be grade 1 out of 5 for C5, grade 0 out of 5 from C6 to C8, grade 1 out of 5 from L2 to L3, grade 0 out of 5 from L4 to L5, and grade 1 out of 5 for S1. Voluntary anal contraction was absent. Hypoesthesia was noted below the C4 dermatome, but no abnormalities were noted in the deep anal pressure, anal sensation, anal reflex, and bulbocavernosus reflex. The neurological level of injury was at C4, tetraplegia with an American Spinal Injury Association Impairment Scale grade of C. Normoactive deep tendon reflexes were present in all four limbs. The patient's cranial nerves were intact.

Cervical spine computed tomography and magnetic resonance imaging scans revealed C3/4 dislocation, prevertebral hematoma at the C2–5 level, and spinal cord contusion at the C3–4 level (Fig. 1). The patient underwent C3–4 posterior fusion and C3–4 anterior cervical discectomy and fusion (ACDF), was intubated and on mechanical ventilation due to the patient's poor respiratory function.

The patient was referred to the Department of Rehabilitation immediately after surgery, where the patient was made to un-

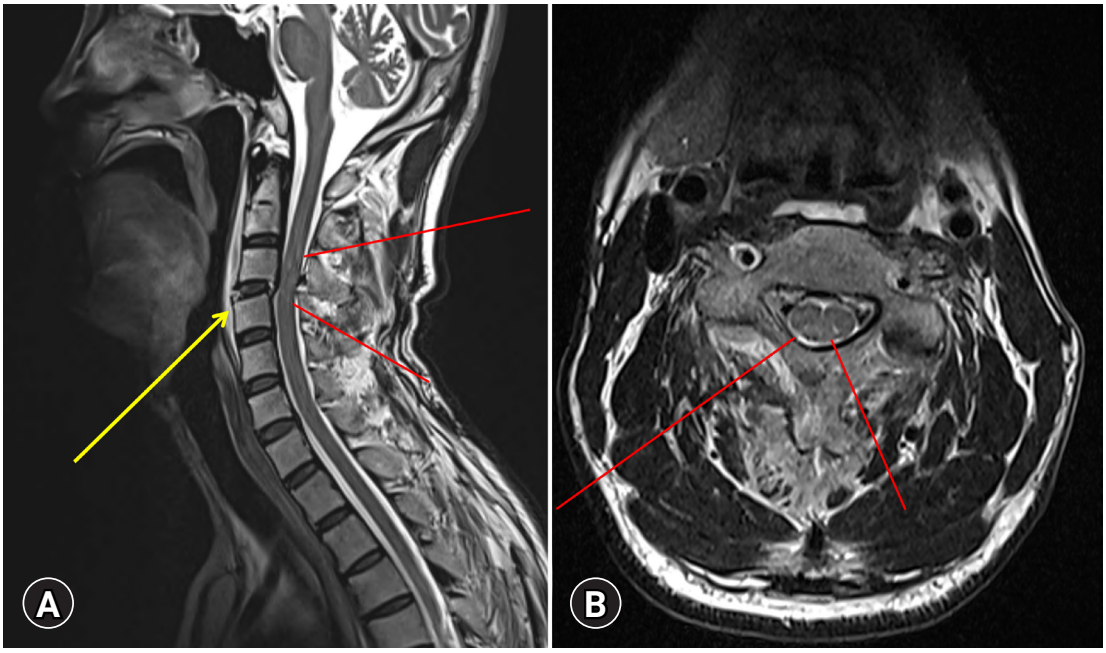

Fig. 1. Cervical spine magnetic resonance image. Magnetic resonance image scan performed when the patient was admitted to the hospital revealed C3/4 dislocation, highly suspicious anterior discoligamentous complex rupture at C3–4, (A) prevertebral soft tissue hematoma at the C2–5 level (yellow arrow), and (A, B) spinal cord contusion with hematoma at the C3–4 level (red lines).

dergo a pulmonary rehabilitation program in the intubated state, including mechanical insufflation-exsufflation, assisted coughing, postural drainage for effective sputum discharge, and air-stacking exercises for lung expansion. Owing to early pulmonary rehabilitation and intensive physical training for improved vital capacity and coughing ability, the patient's breathing pattern stabilized, and the amount of sputum decreased. The ventilator weaning was successful. The peak expiratory flow value through endotracheal tube was measured at 68 L/min. Having considered the cutoff value of peak expiratory flow for successful extubation as 60 L/min [5], we decided to attempt an extubation. However, a dental aspiration was found in the trachea on computed tomography neck on postoperative day (POD) 5. It soon moved to a peripheral bronchus, making it difficult to remove and delaying extubation. Nonetheless, the tooth was removed by bronchoscopy after a second attempt at POD 11, followed by extubation. The total period of intubation was 11 days.

A nasogastric (NG) tube had been inserted the day the patient first visited the hospital to release the gas from stomach. The ileus improved, and through NG tube, the patient started tubal feeding. In the dysphagia screening test conducted by bedside to proceed to an oral feeding, gargling voice, foul-smelling breath during exhalation, and stridor were found. Therefore, we performed FEES to investigate any anatomical abnormalities and vocal cord function on POD 15.

During FEES, it was observed that the cervical metal plate used during ACDF to provide neck stability was found to be exposed through mucosal erosion, and swelling was observed at the ACDF surgical site at the pharynx (Fig. 2). Given the risk of infection, the NG tube was removed, and the patient was nourished with total parenteral nutrition. On POD 23, a follow-up FEES revealed that the exposed area still existed. A literature review in 1990 suggested that perforations less than 2 cm be managed conservatively [6]. Accordingly, since the exposed area was smaller than 2 cm and no signs of infection were found, the patient received conservative therapy, including meropenem, a broad-spectrum antibiotic.

An NG tube could have worsened the mucosal injury. Therefore, on POD 36, the patient underwent a percutaneous endoscopic gastrostomy procedure. While feeding through the percutaneous endoscopic gastrostomy, the patient's general condition improved. Five months after the accident, the patient was discharged. Presently, the patient is still feeding through percutaneous endoscopic gastrostomy. We have been conducting periodic assessments of pharyngeal perforation and dysphagia.

DISCUSSION

Spine surgeries with an anterior neck approach, such as ACDF,

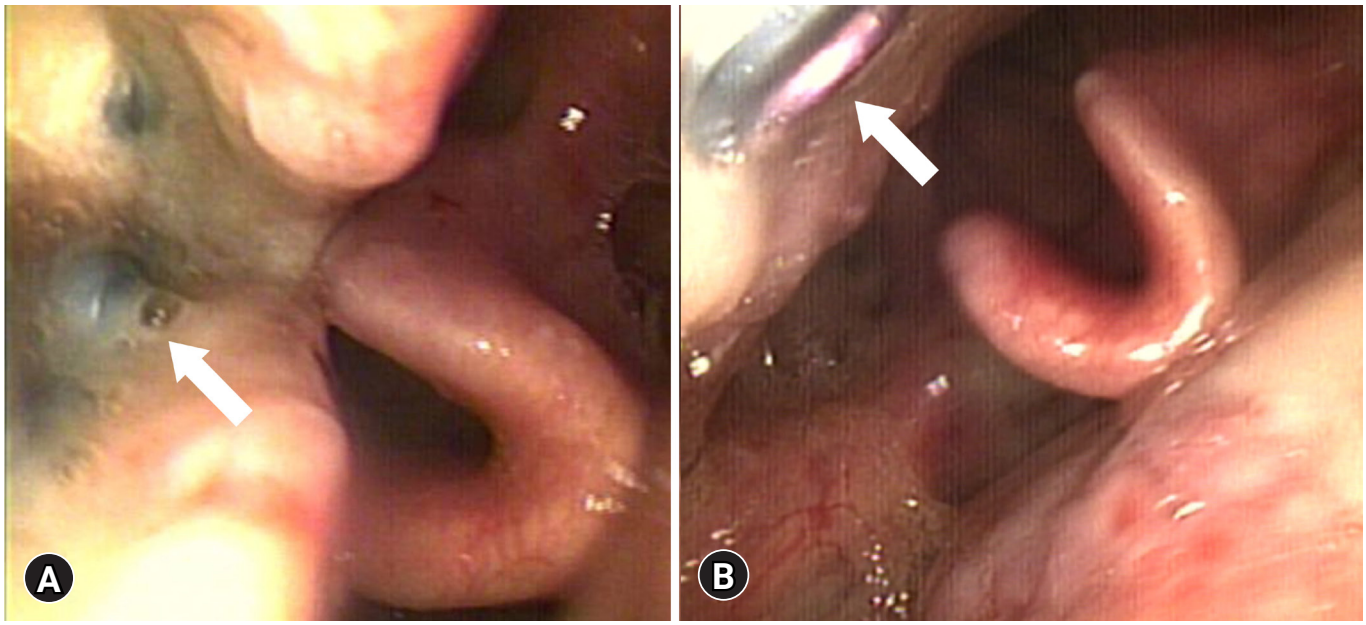

Fig. 2. Pharyngeal perforation seen on fiberoptic endoscopic evaluation of swallowing (FEES). (A) FEES on postoperative day 15. At the anterior cervical discectomy and fusion surgical site at the pharynx, the metal is exposed through mucosal erosion, and swelling is observed (arrow). (B) FEES on postoperative day 23. In the follow-up test, the exposed area is still observed (arrow).

Doihttps://doi.org/10.20408/jti.2022.0016

are commonly performed and are relatively safe surgical procedures. However, the anterior neck region contains various muscles and nerves such as the recurrent laryngeal nerve, superior laryngeal nerve, sympathetic trunk, and spinal accessory nerve, as well as structures such as the thyroid gland, trachea, and esophagus. Due to the complexity of the anterior neck region, complications may occur. In a series of over 850 cases of anterior spine surgery, Cloward [7] reported a wide range of operative complications, most of them being minor and self-limiting. They can be classified into three categories: soft tissue lesions, spinal cord or root injuries, and problems related to spinal stabilization [8].

When soft tissue lesions due to spine surgery are detected, neurosurgical consultation should be obtained to assess the status of fixation and the need for revision, and removal of inciting hardware with vascularized reconstruction with a local pedicled flap. Conservative management such as drainage, broad-spectrum antibiotics, and extraoral feeding is a reasonable option if the patient is in a condition that cannot be operated on, or if the lesion is small and stable.

Major injury or surgery induces a hypermetabolic, catabolic state in which, if not supported by exogenous substrates, excessive skeletal muscle proteolysis occurs, followed by depletion of crucial visceral and circulating proteins. Therefore, early nutritional support benefits high-risk surgical patients [9]. There are many advantages of early enteral feeding in the ICU, such as lower incidence of infection, reduced length of hospital stay [10], immunocompetence, and improved wound healing. Compared to total parenteral nutrition, nutrients delivered through enteral feeding (oral or tubal feeding) are better utilized by the gut. In addition, total enteral feeding prevents gastrointestinal mucosal atrophy, attenuates the injury-stress response, maintains immunocompetence, causes lesser metabolic imbalance, and preserves normal gut flora [9]. Until now, surgeons have been reluctant to initiate early enteral feeding in CSCI patients because of concerns of ileus and other complications. However, studies have found that feeding these patients within the first 72 hours is safe [11].

However, NG tube can cause various complications: gastrointestinal (diarrhea, constipation, nausea, and vomiting), tube-related (nasal ulcers, tube clogging, and tube dislodgement), respiratory (pulmonary aspiration), metabolic (hyperglycemia, hyper or dehydration, electrolytic alterations), and so on [12]. Therefore, it is necessary to examine whether an oral diet is possible and start an oral diet at an early stage of the disease.

There are various screening tools available for dysphagia, including Gugging swallowing screen, 3-oz water test, and citric acid swallowing test in ICU. However, a gold standard test is warranted in patients at a high risk of dysphagia, such as those with CSCI. These gold standard tests include VFSS and FEES.

In patient in this report, mechanical and medical factors such as the ACDF, hematoma formation, injury to the pharynx, and pressure injury due to prolonged placement of the endotracheal tube and NG tube, could be the cause of pharyngeal perforation. A review of the patient's postoperative cervical spine X-ray (lateral view) revealed thinning of the prevertebral soft tissue (Fig. 3). Pharyngeal perforation often does not show any obvious symptoms; we were able to incidentally detect the mucosal defect through FEES, and further determine the direction of treatment and method of feeding.

FEES involves passing a fiberoptic laryngoscope trans nasally to visualize the hypopharynx, larynx, and proximal trachea for the purpose of assessing dysphagia. FEES has the disadvantage that discomfort can be induced because the fiberoptic laryngoscope enters through the patient's nose. Therefore, it is difficult to do FEES to patients who do not cooperate. In addition, it is difficult to observe the oral and upper pharyngeal phases of swallowing.

On the other hand, FEES has several advantages over VFSS. FEES is more reliable in assessing penetration than VFSS and is equally effective in discriminating between penetration and aspiration [13]. FEES allows one to observe the anatomical structure of the oropharynx and vocal cord directly. Therefore, it is possible to check for the presence of vocal cord palsy with phonation. Moreover, patients in the ICU are often difficult to shift out due to the numerous monitoring devices, the patient's poor condition, and the risk of orthostatic hypotension in patients with early SCI. VFSS is possible only when the patient can be brought to the laboratory. In contrast, the endoscope equipment used for FEES has the advantage of being portable and bedside. Therefore, FEES can be a useful test in patients admitted to the ICU with restricted mobility.

The FEES endoscope machine is portable so it can be easily applied at the bedside to patients with suspected PED in the ICU. In addition, FEES allows the identification of anatomical abnormalities of the oropharynx occurring after surgery and abnormalities of vocal cord movement that may occur after extubation. Thus, it is recommended that traumatic CSCI patients with suspected PED be evaluated through FEES.

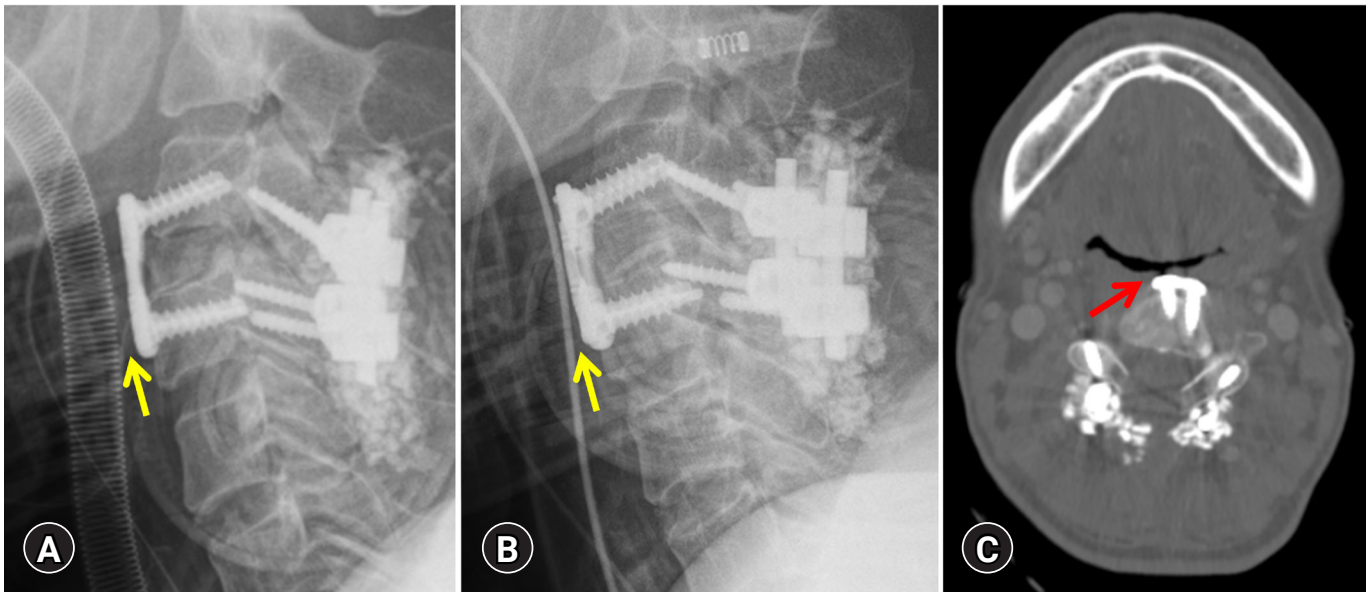

Fig. 3. Cervical spine lateral X-ray on (A) postoperative day (POD) 1 after anterior cervical discectomy and fusion surgery and (B) POD 7. The prevertebral soft tissue appears thinned in front of the surgical site (yellow arrows). (C) Horizontal view of computed tomography neck on POD 22. The cervical metal plate used during anterior cervical discectomy and fusion to provide neck stability was found to be exposed to the hypopharynx (red arrow).

NOTES

Ethical statements

Written informed consent for publication of the research details and clinical images was obtained from the patient.

Conflicts of interest

The authors have no conflicts of interest to declare.

Funding

None.

Author contributions

Conceptualization: all authors; Methodology: YBS; Project administration: MHJ; Visualization: SHH; Writing–original draft: MSC; Writing–review & editing: YBS, MHJ.
All authors read and approved the final manuscript.

REFERENCES

1. Macht M, King CJ, Wimbish T, et al. Post-extubation dysphagia is associated with longer hospitalization in survivors of critical illness with neurologic impairment. Crit Care 2013;17:R119.
2. Seidl RO, Nusser-Muller-Busch R, Kurzweil M, Niedeggen A. Dysphagia in acute tetraplegics: a retrospective study. Spinal Cord 2010;48:197–201.
3. Kirshblum S, Johnston MV, Brown J, O'Connor KC, Jarosz P. Predictors of dysphagia after spinal cord injury. Arch Phys Med Rehabil 1999;80:1101–5.
4. Bath PM, Lee HS, Everton LF. Swallowing therapy for dysphagia in acute and subacute stroke. Cochrane Database Syst Rev 2018;10:CD000323.
5. Smina M, Salam A, Khamiees M, Gada P, Amoateng-Adjepong Y, Manthous CA. Cough peak flows and extubation outcomes. Chest 2003;124:262–8.
6. Niezgoda JA, McMenamin P, Graeber GM. Pharyngoesophageal perforation after blunt neck trauma. Ann Thorac Surg 1990;50:615–7.
7. Cloward RB. Complications of anterior cervical disc operation and their treatment. Surgery 1971;69:175–82.
8. Orlando ER, Caroli E, Ferrante L. Management of the cervical esophagus and hypofarinx perforations complicating anterior cervical spine surgery. Spine (Phila Pa 1976) 2003;28:E290–5.
9. Moore FA, Feliciano DV, Andrassy RJ, et al. Early enteral feeding, compared with parenteral, reduces postoperative septic complications. The results of a meta-analysis. Ann Surg 1992;216:172–83.
10. Marik PE, Zaloga GP. Early enteral nutrition in acutely ill pa-

tients: a systematic review. Crit Care Med 2001;29:2264–70.
11. Dvorak MF, Noonan VK, Belanger L, et al. Early versus late enteral feeding in patients with acute cervical spinal cord injury: a pilot study. Spine (Phila Pa 1976) 2004;29:E175–80.
12. Pancorbo-Hidalgo PL, Garcia-Fernandez FP, Ramirez-Perez C. Complications associated with enteral nutrition by nasogastric tube in an internal medicine unit. J Clin Nurs 2001;10:482–90.
13. Colodny N. Interjudge and intrajudge reliabilities in fiberoptic endoscopic evaluation of swallowing (FEES) using the penetration-aspiration scale: a replication study. Dysphagia 2002;17:308–15.